

Assessment of Biochemical Markers in Two Particular Cases with Maxillary Cysts

MARIUS PRICOP^{1*}, TUDOR RARES OLARIU^{2, 3**}, MARILENA MOTOC^{3, 4}, HORATIU URECHESCU¹, CRISTIANA PRICOP⁵, ANCUȚA BANU¹, ALEXANDRA FAUR⁶, CAMELIA VIDITA GURBAN^{3, 4}

¹Victor Babes University of Medicine and Pharmacy Timisoara, Department of Oro-Maxillo-Facial Surgery, 2 Eftimie Murgu Sq., 300041, Timisoara, Romania

²Victor Babes University of Medicine and Pharmacy Timisoara, Department of Parasitology, 2 Eftimie Murgu Sq., 300041, Timisoara, Romania

³Municipal Clinical Emergency Hospital Timisoara, Clinical Laboratory, 1 Hector Str., 300041, Timisoara, Romania

⁴Victor Babes University of Medicine and Pharmacy Timisoara, Department of Biochemistry and Pharmacology, 2 Eftimie Murgu Sq., 300041, Timisoara, Romania

⁵Victor Babes University of Medicine and Pharmacy, Timisoara, Department of Dental Prosthetics, 2 Eftimie Murgu Sq., 300041, Timisoara, Romania

⁶Victor Babes University of Medicine and Pharmacy Timisoara, Department of Anatomy and Embryology, 2 Eftimie Murgu Sq., 300041, Timisoara, Romania

Biochemical markers have been previously described as predictors of bone remodelling in dental disorders. Here we present 2 cases, diagnosed with inflammatory maxillary cysts in whom biochemical markers of bone remodeling have been evaluated. Clinical evaluations, radiological and laboratory tests, including histopathological examinations were performed in both patients. Laboratory test results indicated an activation of osteoblasts in both cases. Bone alkaline phosphatase (BAP) serum levels, as a marker for bone deposition, were significantly increased in both patients. In addition, differences in the cyst size and the tartrate-resistant acid phosphatase (TRACP-5b) test results have been noted in these cases. In the first case, with a cyst < 1.5 cm in diameter, TRACP-5b serum levels were within the normal reference laboratory values, suggesting that the process of bone resorption may be slightly decreased or potentially lacking. In the second case, with a cyst > 3 cm in diameter, TRACP-5b serum levels were 1.5 times higher than the upper limit of the normal reference laboratory values, suggesting that a process of osteolysis apparently occurred. The two cases diagnosed with maxillary cyst presented differences in the size and the TRACP-5b test results. This suggests a possible correlation between TRACP-5b serum levels, bone resorption and the size of maxillary cysts. Further studies should be performed to confirm this hypothesis.

Keywords: biochemical markers, maxillary cysts, osteoblasts, bone alkaline phosphatase (BAP)

Maxillary cysts are hollow endobone formations that arise from the existing epithelial tissue proliferation in the thickness of the maxillary bone spongiosa. The Malassez epithelial cells are located around the tooth root and proliferate under the influence of a chronic inflammatory process that will finally determine a granuloma [1]. The increase in size of the granuloma will result in a decrease of the normal blood supply. This will cause lyses of the epithelial cells, and determine microcysts formation. A bone resorption will progressively occur [2, 3].

When a bone injury occurs, this is followed by phases of reparative, [4,5] or so called remodeling process. The remodeling cycle consists of three consecutive phases: resorption, when osteoclasts digest old bone; reversal, when mononuclear cells appear on the bone surface; and formation, when osteoblasts lay down new bone until the resorbed bone is replaced [6,9].

Biochemical markers have been previously described as predictors of bone remodelling in dental disorders [6]. Here we present 2 interesting cases, diagnosed with inflammatory maxillary cysts (IMC) in whom biochemical markers of bone remodeling have been evaluated. Clinical, radiological and laboratory tests, including histopathological examinations were performed in both patients.

Experimental part

Materials and methods

Patients were clinically and radiologically diagnosed with maxillary cysts and admitted to the Oral and Maxillofacial Surgery Clinic of the Municipal Clinical Emergency Hospital in Timisoara, Romania, between September-December 2016. Serum markers of bone remodeling, bone alkaline phosphatase (BAP) for bone deposition, and tartrate-resistant acid phosphatase (TRACP-5b) for bone resorption, were determined by the enzyme immunoassay technique (ELISA). Serum levels of Calcium ions (Ca^{2+}) and Magnesium (Mg^{2+}) were determined by the colorimetric spectrophotometric technique using VITROS-950 Chemistry-System. Complete blood count was performed by the photometric cells technique using the analyzer ADVIA-2120. Histopathological examinations were performed in both patients using the hematoxylin eosins staining (HE).

Case reports

Case 1: A 33-year, female, was diagnosed and hospitalized with a right, medium sized, maxillary cystic formation. Physical examination revealed a tumor, hard in consistency, in the right upper vestibule, which determined a slight deformation of the alveolar vestibular plate,

* email: rolariu@yahoo.com

**These two authors contributed equally to this work

adjacent to the 1.2 tooth (fig. 1a). A retroalveolar radiography was performed, showing a unilocular, net shaped, radiolucent image, measuring 1.3/1.0 cm in size and presenting a 1.2 periapical location (fig. 1b). The histopathological examination revealed a cyst wall bordered by squamous epithelium with a rich inflammatory infiltrate; a mixed inflammatory infiltrate (lymphocytes and plasmocyte cells) and fibrosis in the wall thickness (HEx200) (fig. 1c). The relevant laboratory test results are presented in table 1.

Case 1:

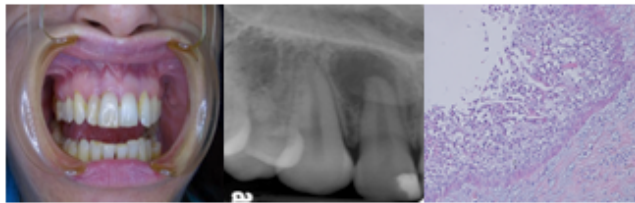


Fig. 1.

Case 2: A 44-year, male, was diagnosed and hospitalized with a left, large sized mandibular cystic formation. Physical examination revealed a painless tumor, hard in consistency, located in the posterior area of the lower left vestibule, that deformed the left mandible angle and extended to the left mandible ramus (fig. 2a). A cone beam computed tomography (CBCT) was performed, showing a unilocular cyst, with a net contour, around 3.8 dental apex and extended to the left mandibular ramus, measuring 3.2/3.0/3.5 cm in diameter (fig. 2a, 2b). The histopathological examination revealed a wall cyst with mixed inflammatory infiltrate including lymphocytes, plasmocytes, macrophages and multinucleated giant cells; associated granulomatous reactions were observed with multinucleated giant cells on acicular cholesterol crystals (HEx200) (fig. 2c). The relevant laboratory test results are presented in table 1.

Case 2:

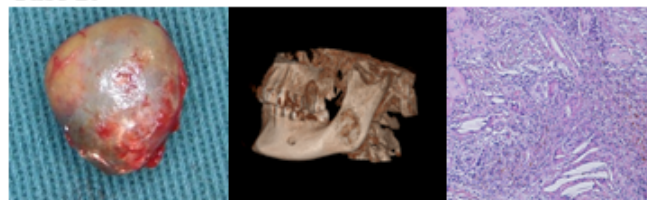


Fig. 2.

by the hydrostatic expansion caused by the imbalance of osmotic intracystic pressure and the blood serum, concurrently with the multiplication of the cystic wall cells. An adjacent bone resorption follows this process and precedes the bone formation [1, 7, 10]. Bone resorption is more intense, but it takes less time and is performed in a single cell layer by the activation of osteoclasts. Resorption surfaces are characterized by their irregular configuration due to the presence of osteoclasts [2, 3]. Osteoblasts have a great capacity of regeneration. During the active period, osteoblasts secrete a large amount of bone alkaline phosphatase. The bone formation is carried out in successive layers, the newly formed smooth bone areas being covered by active osteoblasts [6, 11].

Laboratory test results in our patients, including the erythrocyte sedimentation rate (ESR), complete blood counts (CBC), C-reactive protein (CRP) and fibrinogen (FBG) tended towards the upper limit of normal reference laboratory values (NLRV), suggesting lack of a systemic inflammatory process (table 1). However, results of the histopathological examination, in both patients, revealed a local inflammatory process described as a mixed inflammatory infiltrate with lymphocytes, plasmocytes, macrophages and multinucleated giant cells (figs. 1c and 2c).

Our results indicate an activation of osteoblasts in both cases. BAP serum levels, as a marker for bone deposition [2,3,6], were significantly increased in both patients: 3 and 4.75 times higher than the upper limit of NLRV in the first and second case, respectively (table 1). This process of bone regeneration was suggested by an increase of BAP serum levels in both cases (table 1). The gradual increase of the inflammatory odontogenic cyst may be achieved by exerting a bone pressure. This includes a process of bone remodelling with a significant increase of osteoblasts activity compared to osteoclasts, which were minimally activated [3,12].

TRACP-5b has been described as a marker of the bone resorption process [6,9,12]. In the first case, with a small cyst, <1.5 cm, TRACP-5b serum levels were within NLRV, suggesting that the process of bone resorption may be slightly decreased or potentially lacking. In the second case, with a larger cyst, >3 cm diameter, TRACP-5b serum levels was 1.5 times higher than the upper limit of NLRV, suggesting that a process of osteolysis apparently occurred.

Laboratory Tests	Case 1	Case 2	NRLV
WBC ($\times 10^3/\mu\text{L}$)	10.2	10.7	4.8 - 11
NEUT (%)	65	66.5	53 - 68
ESR (mm/1h)	10	11	2 - 12
FBG (mg/dL)	320	335	180 - 350
CRP (mg/L)	4.5	5.5	0.1 - 6
BAP ($\mu\text{g/L}$)	26.92	41.75	8.5 - 8.7
TRACP-5c (U/L)	3.55	6.5	1.5 - 4.3
Ca ²⁺ (mg/dL)	4.2	4.5	3.5 - 4.8
Mg ²⁺ (mg/dL)	2.3	2.4	1.6 - 2.6

(WBC=leukocytes, NEUT=neutrophils, ESR= erythrocyte sedimentation rate, CBC=complete blood counts, CRP=C-reactive protein, FBG=fibrinogen, NRLV=normal reference laboratory values)

The periapical inflammatory process stimulates the Malassez epithelial debris that remains from tooth development, proliferating and turning into cysts. The mechanism responsible for cyst growth may be explained

Conclusions

The two cases diagnosed with maxillary cyst presented differences in the size and the TRACP-5b test results. This suggest a possible correlation between TRACP-5b serum levels, bone resorption and the size of maxillary cysts. Further studies should be performed to confirm this hypothesis.

Table 1

RESULTS OF THE LABORATORY TESTS PERFORMED

References

1. LIN L.M., et al. JSM Dent Surg; 2(2), 2017, p.1017-19.
2. VAISMAN D.N., et al. Biol Trace Elem Res; 104, 2005, p.131-40.
3. ASMA A.A., et al. Sains Malaysiana, 40(10), 2011, p.1147-51.
4. LAZARIUC, D., AGOP FORNA, D., FORNA, N.C., Mat. Plast., 53, no. 3, 2016, p. 561
5. LUCHIAN, I., MARTU, I., MARTU, C., GORIUC, A., BELDIMAN, A., MARTU, S., Rev. Chim. (Bucharest), 67, no. 6, 2016, p. 1073
6. DUVINA M., et al. Clinical Cases in Mineral&Bone Metabolism, 9(2), 2012, p.100-106.
7. HADJIDAKIS J.D., et al. Ann. N.Y. Acad. Sci., 1092, 2006, p.385-396.
8. AGOP FORNA, D., FORNA, N.C., EARAR, K., POPESCU, E., Mat. Plast., 54, no. 2, 2017, p. 312
9. POPESCU, E., AGOP FORNA, D., EARAR, K., FORNA, N.C., Mat. Plast., 54, no. 2, 2017, p. 390
10. SHAHRUL H.Z., et al. Sains Malaysiana, 39(3), 2010, p.405-12.
11. SANTOS V.R., et al. Rev. Odonto. Cienc., 25(1), 2010, p.54-58.
12. LERNER U.H., et al. J Dent Res, 85(7), 2006, p.584-95.

Manuscript received: 21.03.2017